ASE POSITION PAPER

Contrast Echocardiography: Current and Future Applications

American Society of Echocardiography Task Force on Standards and Guidelines for the Use of Ultrasonic Contrast in Echocardiography; Sharon L. Mulvagh, MD, Chair, Anthony N. DeMaria, MD, Cochair, Steven B. Feinstein, MD, Peter N. Burns, PhD, Sanjiv Kaul, MD, James G. Miller, PhD, Mark Monaghan, PhD, Thomas R. Porter, MD, Leslee J. Shaw, PhD, and Flordeliza S. Villanueva, MD, *Rochester, Minnesota; San Diego, California; Chicago, Illinois; Toronto, Ontario, Canada; Charlottesville, Virginia; St Louis, Missouri; London, United Kingdom; Omaha, Nebraska; Atlanta, Georgia; and Pittsburgh, Pennsylvania.*

Recent updates in the field of echocardiography have resulted in improvements in image quality, especially in those patients whose ultrasonographic (ultrasound) evaluation was previously suboptimal. Intravenous contrast agents are now available in the United States and Europe for the indication of left ventricular opacification and enhanced endocardial border delineation. The use of contrast enables acquisition of ultrasound images of improved quality. The technique is especially useful in obese patients and those with lung disease. Patients in these categories comprise approximately 10% to 20% of routine echocardiographic examinations. Stress echocardiography examinations can be even more challenging, as the image acquisition time factor is critically important for accurate detection of coronary disease. Improvements in image quality with intravenous contrast agents can facilitate image acquisition and enhance delineation of regional wall motion abnormalities at the peak level of exercise. Recent phase III clinical trial data on the use of Optison and several other agents (currently under evaluation) have revealed that for approximately half of patients, image quality substantively improves, which enables the examination to be salvaged and/or increases diagnostic accuracy. For the "difficult-to-image" patient, this added information results in (1) enhanced laboratory efficiency, (2) a reduction in downstream testing, and (3) possible improvements in patient outcome. In addition, substantial research efforts are underway to use ultrasound contrast agents for assessment of myocardial perfusion. The detection of myocardial perfusion during echocardiographic examinations will permit the simultaneous assessment of global and regional myocardial structure, function, and perfusion—all of the indicators necessary to enable the optimal noninvasive assessment of coronary artery disease. Despite the added benefit in improved efficacy of testing, few data exist regarding the long-term effectiveness of these agents. Currently under evaluation are the clinical and economic outcome implications of intravenous contrast agent use for daily clinical decision making in a variety of patient subsets. Until these data are known, this document offers a preliminary synthesis of available evidence on the value of intravenous contrast agents for use in rest and stress echocardiography. At present, it is the position of this guideline committee that intravenous contrast agents demonstrate substantial value in the difficult-to-image patient with comorbid conditions limiting an ultrasound evaluation of the heart. For such patients, the use of intravenous contrast agents should be encouraged as a means to provide added diagnostic information and to streamline early detection and treatment of underlying cardiac pathophysiology. As with all new technology, this document will require updates and revisions as additional data become available. (J Am Soc Echocardiogr 2000;13: 331-42.)

From the American Society of Echocardiography, Raleigh, NC.

Reprint requests: American Society of Echocardiography, 4101 Lake Boone Trail, Suite 201, Raleigh, NC 27607.

Copyright © 2000 by the American Society of Echocardiography.

0894-7317/2000 $12.00 + 0 27/1/105462

doi:10.1067/mje.2000.105462

INTRODUCTION

New ultrasonographic (ultrasound) contrast agents and new imaging technologies to detect them have recently become available to the echocardiography laboratory. Intravenous (IV) injection of ultrasound contrast

Table 1 Echocardiographic contrast agents that have been approved* by the Food and Drug Administration or are under development

Name	Shell composition	Gas	Manufacturer
Albunex* / Infoson	Albumin	Air	Mallinckrodt
Optison* (FS069)	Albumin	Air / PFP	Mallinckrodt
PESDA	Albumin	Air / PFC	T. Porter
Sonazoid (NC100100)	Lipid	Air / PFC	Nycomed
Definity (DMP115)	Lipid	Air / PFP	Dupont
Imagent (AFO150)	Surfactant / powder	Air / PFC	Alliance / Schering
Sonovue (BR1)	Surfactant / powder	Air / SF6	Bracco
Levovist	Galactose / Palmitate	Air	Schering / Berlex
BY 963	Lipid	Air	Byk-Gulden
EchoGen	Surfactant	PFC	Sonus
PB-127	Bilayer	Nitrogen	Point Biomedical
AI-700	Polymer	Air / PFC	Acusphere

PFP, Perfluoropropane; *PFC,* perfluorocarbon.

agents has been documented to improve endocardial border delineation.[1] Contrast enhancement of the blood-tissue boundary enables improved assessment of ventricular wall motion, wall thickness and thickening, calculation of ejection fraction, and delineation of cardiovascular structural abnormalities. Experimental results indicate that contrast has the potential to provide qualitative and quantitative assessment of myocardial perfusion and coronary blood flow.

As with all emerging technologies, criteria for appropriate application need to be developed. Indeed, the proliferation of new medical technology has been a major factor contributing to the rising cost of health care.[2] During the past 2 decades, a number of new and innovative techniques have been introduced to diagnostic cardiology that have resulted in improved test performance, but at a higher cost. Historically, as new technology has been developed, it has been expected that payers would reimburse for imaging tests without requiring justification of the incremental cost of the new technology. Today medical societies, such as the American Society of Echocardiography, are taking the lead in providing a thorough synthesis of available evidence justifying adoption of relevant new technology. The purpose of this paper is to review recent developments in contrast echocardiography and to propose standards and guidelines for the appropriate application of this technology on the basis of published scientific evidence.

BACKGROUND

Contrast Agents

The ability to opacify vascular structures with strong echoes (or "contrast") on echocardiograms by injecting agitated saline solution or other fluids containing gas bubbles has been recognized for over 30 years.[3] The primary mechanism by which injection of such fluids produces ultrasound contrast was determined to be increased backscatter from inclusions of microbubbles within the injectant. Such microbubbles markedly enhanced the blood echo by introducing multiple liquid-gas interfaces. However, those microbubbles of room air, which were small enough to pass through the microcirculation (red blood cell size; ie, <8 μm), dissolved rapidly in blood and lost their echogenicity. Early attempts to encapsulate the bubbles resulted in agents with improved stability but of a size too large to traverse the pulmonary microvasculature. Therefore, early contrast echocardiography by IV injection was used primarily to detect cardiac shunts or examine right heart structures. The invasive administration of contrast agents directly into the central circulation or pericardial cavity was use to image the left ventricular (LV) cavity and the great vessels and to assist in determining needle location during pericardiocentesis. With the use of such approaches, numerous studies have validated the benefit of contrast echocardiography in the detection of atrial and ventricular septal defects, patent foramina ovale, congenital anomalies,[4,5] and in the assessment of the placement of intrapericardial catheters.[6] Moreover, invasive assessment of myocardial perfusion has been achieved by direct injection of contrast agents into the heart or coronary arteries.[7-11]

Recently, new ultrasonic contrast agents (Table 1) have been developed, which are characterized by both smaller mean size and prolonged persistence. Various techniques are used to combine materials that control the bubble surface ("shells") with gases that inhibit diffusion and bubble dissolution (eg, perfluorocarbons). These new contrast agents can be

visualized in the LV chamber and myocardium after IV injection.

New Ultrasound Imaging Technologies

Simultaneous with the emergence of novel agents, new ultrasound technologies have been developed to improve microbubble detection. Enhancement of both the intensity and duration of the detection of microbubbles has resulted from technologic advances exploiting the interactions that occur between microbubbles and the incident ultrasound field.[12,13] Some of these advances, such as harmonic and pulse inversion imaging, have already been introduced into clinical echocardiographic practice, while others are in rapid evolution. Harmonic imaging[14-16] substantially enhances the detection of contrast within the cardiac chambers during clinical assessments,[17,18] is commercially available, and can readily be used in patients undergoing echocardiography. New and evolving approaches to ultrasound delivery preferentially enhance the visualization of microbubbles within the microcirculation of the myocardium.[19-21] These emerging technologies have demonstrated investigational evidence for detection of myocardial perfusion with contrast echocardiography and are evolving in their design and application.

Nonlinear harmonic imaging. Harmonic imaging results in enhanced detection of ultrasound contrast agents through exploitation of the differences between the response of solid tissue and contrast microbubbles to the ultrasound energy. Soft tissues are linear scatterers, meaning that the echo they create is a scaled version of the insonifying sound. Ultrasound contrast agents, on the other hand, oscillate in an asymmetric way in the ultrasound field and give rise to nonlinear echoes that contain new acoustic information. With a linear scatterer, insonifying at a given frequency produces a response only at that frequency, which is what occurs during conventional (or "fundamental") imaging. However, with a nonlinear scatterer, insonifying at a given frequency produces responses at multiples of that frequency. Multiples of the transmitted frequency are termed "harmonics." The second harmonic is used in clinical echocardiographic imaging. Thus a second harmonic imaging system might transmit at a frequency of 1.7 MHz and receive at the frequency 3.4 MHz. It happens that at high transmittal intensities, propagation of ultrasound through tissue is somewhat nonlinear, so harmonics build up as the beam penetrates tissue. Thus signals from the myocardium and surrounding tissue are not entirely absent in harmonic imaging, but regions perfused by a highly nonlinear contrast agent appear substantially brighter. The nonlinear response of microbubbles is greatest at their resonant frequency. Fortuitously, the range of ultrasound frequency used clinically (2 to 5 MHz) coincides with the resonant frequencies of microbubbles small enough for transpulmonary passage (less than 6 to 10 microns), thus making harmonic imaging highly effective for ultrasound contrast studies.

Understanding ultrasound and microbubble interactions: Emergence of newer imaging techniques. Most ultrasound contrast agents can be destroyed, at least partially, by the interrogating ultrasound field itself[19,22] eliminating the targets for imaging. Current ultrasound equipment has acoustic output information available to the user. The mechanical index (MI) is an estimate of the peak negative pressure of the sound field at its focus, normalized to the transmitted frequency. The MI is now routinely displayed and can be readily adjusted on most equipment.

To control microbubble destruction[19] and enable detection (and potentially, quantification) of myocardial perfusion,[23] ultrasound transmission may be delivered in an interrupted manner. This is usually accomplished by obtaining a single image gated to the electrocardiogram, but newer approaches that use multiple ultrasound pulses to detect and destroy microbubbles are also available.[24,25] The most recent advances and refinements in harmonic imaging and Doppler technology have enabled visualization of tiny amounts of contrast with very high spatial resolution, obviating the need for intermittent delivery of ultrasound and permitting the real-time clinical assessment of myocardial perfusion.[26,27]

CONTRAST ECHOCARDIOGRAPHY: CURRENT INDICATIONS

In the United States and Europe, the Food and Drug Administration (FDA) and European Union, respectively, have approved several echocardiographic contrast agents for the indication of ventricular opacification and enhancement of endocardial border definition in patients with technically suboptimal echocardiograms. Left ventricular cavity opacification (LVO) is of clinical value for the assessment of cardiac structure and ventricular performance in resting and stress echocardiography. In addition, contrast agents may be used for the enhancement of Doppler signals needed to evaluate diastolic and valvular function.

Enhancement of Endocardial Border Delineation

Cardiovascular structure and function assessment. Contrast opacification of left heart structures

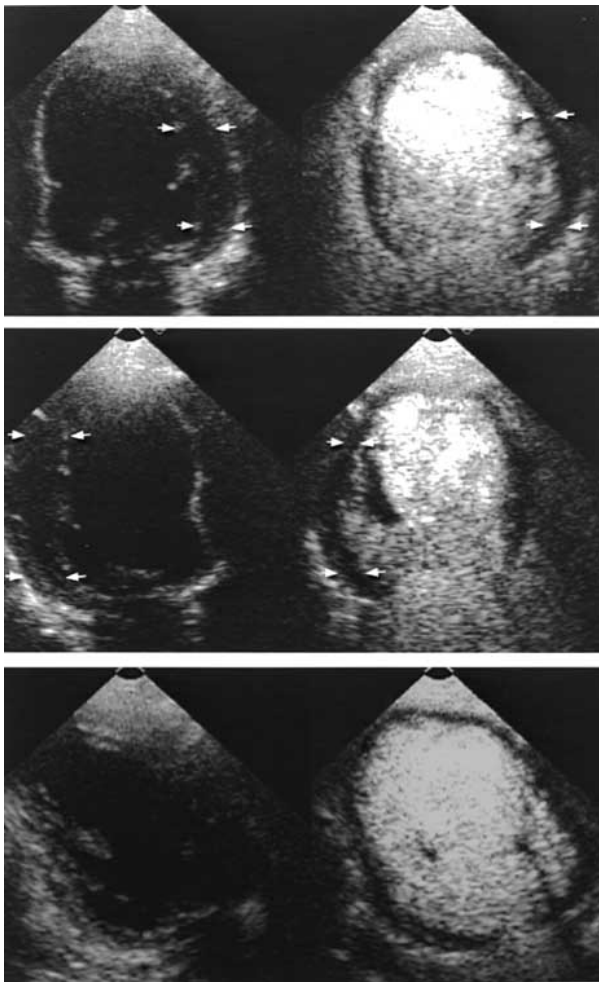

Figure 1 Two-dimensional still frame end-diastolic images from a 48-year-old male patient with dilated cardiomyopathy. *Left panels,* Noncontrast harmonic images. *Right panels,* Contrast harmonic images (Optison, 0.5 mL intravenous bolus). *Top row,* apical 4-chamber view; *middle row,* apical long-axis view; *bottom row,* apical 2-chamber view. Left ventricle is on right, apex at top. *Arrows* indicate apparent myocardial borders. Note improved visualization of endocardial border with contrast.

after IV injection has now been achieved with several microbubble agents (Figure 1). Sonicated human serum albumin (Albunex) was the initial agent approved for this application. Multicenter data established the ability of an IV Albunex injection to enhance the echocardiographic diagnosis of LV size and function.[28] Unfortunately, the consistency with which diagnostic studies could be obtained with this agent was disappointing, mainly because of the fragility and short duration of the effect of the air-containing microbubbles. Newer contrast agents containing low solubility gases and/or surface-stabilizing shells have been shown to achieve studies of diagnostic quality more reliably. In a multicenter study of more than 200 patients in whom LV opacification was produced by a commercially available agent (Optison), the degree of LV opacification, the number and length of LV endocardial border segments visualized, and the duration of contrast enhancement achieved were significantly superior to that resulting from Albunex.[1] The patient cohort was selected on the basis of suboptimal baseline echocardiograms with nonvisualization of at least 2 of 6 segments in the apical 4-chamber view. Contrast administration in these patients converted a nondiagnostic study to a diagnostic echocardiogram in 75% of those examined. This added improvement in image quality resulted in a greater ability to answer the primary referral question in as many as 50% of patients.[29] In terms of physician assessment, diagnostic information (ie, added value) increased 35% to 40% with the use of contrast echocardiography in patients selected for suboptimal image quality.[29] Similar findings have been observed after LV opacification produced by IV injections of investigational contrast agents.[30,31] Administration of an IV contrast agent has also been shown to enable more accurate measurement of LV volume and ejection fraction in human beings, and is most useful in subjects with 2 or more adjacent endocardial segments not seen at baseline.[32] It has also been demonstrated clinically that with the use of contrast, harmonic imaging produces improvements over fundamental imaging in LVO, endocardial border definition, and reviewer confidence in the assessment of systolic function.[17,18,33,34]

Intravenous injections of contrast have utility in defining altered cardiovascular anatomy. Detection of complications of myocardial infarction, such as myocardial rupture and LV pseudoaneurysm formation, has been facilitated with IV contrast injections.[35] Echocardiographic contrast has also been used to enhance the diagnostic capability of transesophageal echocardiography in suspected ascending aortic dissection by clearly identifying true and false lumina.[36] Space-occupying masses within cardiac chambers, such as thrombi and/or tumors, may also be more easily identified with the use of intravenously injected intracavitary contrast.[37] Enhanced definition of left and right ventricular morphology may be achieved, which may be particularly valuable in the assessment of asymmetric hypertrophic and right ventricular dysplastic syndromes.[38]

Beyond enhanced assessment of ventricular function and cardiac structure in the technically challenging patient presenting in the echocardiography laboratory setting, significant application for contrast

Table 2 Technical guidelines for LVO harmonic contrast studies

Ultrasound Machine Settings
Set Mechanical Index (MI): 0.4-0.6
Select harmonic imaging
Optimize transmit focus location (usually far-field; may be apical)
Optimize TGCs and gain
Minimize near-field gain
Use and modify contrast presets supplied by specific vendors
Intravenous Contrast Injection
Rest Study
0.5 mL of Optison IV bolus (0.5-1.0 mL/s)
Slow NaCl flush (2-3 mL over 3-5 seconds)
When contrast is seen in right ventricle, *stop flush*
Additional IV doses of 0.2–0.3 mL Optison if required
Stress Study
Rest imaging as above
Low dose and peak Dobutamine
0.5 mL of Optison IV bolus in dobutamine line
Dobutamine infusion acts as flush
If clinical reasons require termination of dobutamine infusion:
Use NaCl flush (2-3 mL over 3-5 seconds)
If attenuation at rest with 0.5 mL Optison:
Decrease dose to 0.3–0.4 mL at peak
Additional doses of 0.2–0.3 mL (if needed)
Peak Exercise
While on treadmill, inject 30 seconds before exercise termination
If bicycle exercise, inject at peak stress stage (at beginning if 2-minute stage; at 1 minute if 3-minute stages used)
Inject optimal rest dose with NaCl flush as above
Transfer to imaging bed
Additional 0.2-0.3 mL Optison IV as required with slow NaCl flush
Image Acquisition: Practical Guidelines
Start at apical window; use bed with cutout
To improve image quality and decrease shadowing:
Use respiratory movements
Move transducer position (more laterally)
If shadowing cannot be eliminated:
Attempt to direct shadow through center of left ventricle
If apex is underfilled with contrast:
Reduce MI
Inject more contrast
Use larger and more rapid saline flush
If attenuation:
Wait; increase MI

LVO, Left ventricular opacification; *TGC,* time gain compensation; *IV,* intravenous.

exists in patients presenting in other clinical environments. The bedside use of contrast echocardiography to assist in adequate image acquisition in the supine, mechanically ventilated, intensive care, or emergency room patient can be helpful. Previously, the clinician could resort only to a transesophageal echocardiography or nuclear study, but contrast-enhanced transthoracic echocardiography imaging can frequently provide the required information, without the need for an alternative testing method.[29]

Stress echocardiography. Accurate assessment of global and regional LV systolic performance is essential to the evaluation of coronary artery disease. Because the criteria for ischemia are based on the detection of contractile dysfunction in any myocardial segment, complete visualization of all LV walls is necessary to document or exclude abnormalities confidently. Two-dimensional stress echocardiography has shown high sensitivity and specificity in the detailed evaluation of regional wall motion, cavity size, and LV function at rest and peak stress induced by either exercise or pharmacologic means.[39,40] Stress echocardiography has also been shown to predict cardiovascular outcome accurately in patients with normal[41] and abnormal results.[42-44] However, interpretation of stress echocardiograms is qualitative, and multiple factors may produce suboptimal image quality and decreased endocardial border def-

inition, leading to diminished diagnostic accuracy. Impaired transmission of sound energy caused by body habitus and/or lung disease, as well as the challenges imposed by excessive cardiac motion resulting from hyperventilation and tachycardia, can result in nondiagnostic images in up to 30% of patients.[45] In addition, suboptimal studies can lead to interobserver variability and reduced reproducibility. Interinstitutional observer variance in stress echocardiography interpretation has been reported to decline substantially from 100% agreement to 43% agreement in those studies with the lowest image quality.[46] Investigations that used the earliest IV contrast agents found incremental improvement in the reproducibility of stress echocardiography by producing greater than 80% improvement in endocardial border definition.[47-49] With the newer contrast agents, essentially complete LVO can be reliably obtained, resulting in up to 95% improvement in endocardial border resolution.[50] The improvements in endocardial border definition are especially helpful in the anterior and lateral regions, which are often difficult to visualize.[50] Improved reproducibility in the quantitative analysis of LV function, both at rest and during stress, has also been reported.[51]

Contrast echocardiography may provide increased accuracy in the stress echocardiography diagnosis. Harmonic imaging of a second-generation contrast ultrasound agent permits homogenous and persistent LV opacification with significantly improved image quality, completeness of wall segment visualization, and reviewer confidence.[52] Importantly, early studies indicate that the substantial improvement in diagnostic accuracy afforded by use of contrast may contribute to a cost-effective pattern of care.[29,53,54] This is achieved through (1) the impact on downstream repetitive testing in patients with an initially nondiagnostic echocardiogram, (2) a reduced rate of false-positive and false-negative echocardiograms as a result of improved image quality, and (3) increased laboratory efficiency in evaluation of the labor-intensive, difficult-to-image patient. Large-scale clinical studies are underway to evaluate contrast use in stress echocardiograms of patients with other than suboptimal images at rest. These studies were designed to further objectively define patient population subsets most likely to benefit from contrast and to assess the impact on resources.

To achieve optimal LVO results and avoid common pitfalls with contrast echocardiography as practiced in the current clinical environment, several basic guidelines for equipment setup, contrast agent administration, and image acquisition are provided in Table 2. An important key to success in LVO contrast imaging that cannot be overemphasized is the correct adjustment of the acoustic output level (MI); use of a lower MI will provide more homogenous intracavity and endocardial contrast effect, especially in the apical regions. As only one contrast agent is available clinically in the United States at the time of writing, the guidelines refer primarily to this agent. However, as other agents become available, specifics will need to be modified. The general imaging principles should remain valid, nonetheless.

Doppler Enhancement

Recordings of blood flow velocity by echocardiographic Doppler methods have long been applied to estimating intracardiac pressures and transvalvular gradients. Contrast enhancement produced by hand agitation of the saline solution has traditionally been used for enhancement of right-sided Doppler flow velocity signals.[55] This technique has been limited to the noninvasive assessment of pulmonary artery systolic pressure by analysis of tricuspid regurgitant signals.

The advent of contrast agents capable of traversing the pulmonary vasculature enables clinical application of the contrast-enhanced Doppler technique to the assessment of left-sided valvular lesions.[56] Amplification of Doppler signals has been shown to be of great value in aortic stenosis, which poses a frequent challenge in the obtainment of representative peak velocities across the stenosed valve. In one clinical study, contrast-enhanced Doppler recordings across stenotic aortic valves provided clear spectral signals in 9 of 10 patients in whom they could not be recorded otherwise, and the gradients calculated from these signals correlated well with those of catheterization.[57] Transmitral and pulmonary venous flow velocities can also be enhanced by contrast agents, permitting more complete diastolic function assessments, especially in patients with faint signals and in those with mitral inflow patterns suggestive of pseudonormalization. It is very important to adjust gain settings and use only small amounts of contrast when assessing Doppler spectral profiles to avoid overestimation of spectral velocities caused by the blooming effect.[58] Color flow Doppler enhancement has also been demonstrated with transpulmonary contrast agents,[59] but clinical application of these observations is yet evolving.

FUTURE APPLICATIONS

At present, the US FDA has approved 2 contrast agents (Albunex and Optison). Several additional

agents have been approved in other countries. These agents have been approved only for the indication of ventricular cavity and endocardial border enhancement. A multitude of additional agents are under development and in various phases of the regulatory approval process (Table 1). Although clinically useful as endocardial border-enhancing agents, ultrasound contrast agents have the greater potential to permit assessment of myocardial perfusion with noninvasive, nonionizing, portable imaging methods, which has fueled the continuing development of newer agents.

Myocardial perfusion detection achieved by the direct intracoronary arterial injection of experimental microbubbles, generally produced from hand-agitated or sonicated radio-opaque contrast dyes, has been extensively investigated in animal and human studies. These investigations have shown intracoronary myocardial contrast echocardiography to be a reproducible, reliable technique for the evaluation of (1) the area at risk for necrosis after acute coronary occlusion,[9] (2) regional coronary flow reserve and transmural perfusion relationships,[60] (3) collateral myocardial blood flow,[10] (4) myocardial viability,[11,61-63] and (5) the outcome of cardiac reperfusion interventions.[64-68] Resting myocardial perfusion defects, assessed by intracoronary injections of microbubbles, have been correlated to radionuclide perfusion assessment techniques in animals (microspheres) and humans (99mTc-sestamibi single-photon emission computed tomography [SPECT]), respectively.[69,70] However, the FDA has not approved any ultrasound contrast agent for intracoronary use.

Intravenous administration of contrast has an emerging role in the assessment of myocardial perfusion. Several recent studies with intravenously administered contrast agents in conjunction with newer imaging techniques have reported a clear delineation of the spatial distribution of nonperfused myocardium during experimental coronary artery occlusion and reperfusion.[71-78] In addition, regional myocardial perfusion abnormalities during pharmacologic stress (induced by both dobutamine and adenosine) have been demonstrated to occur in experimental and clinical stress-induced ischemia.[79,80] In initial studies during dipyridamole stress testing, regional myocardial perfusion abnormalities identified with intermittent contrast harmonic imaging have correlated well with regional radionuclide tracer distribution.[81] Preliminary experimental studies have suggested that quantitative measurements of myocardial videointensity from intermittent harmonic imaging during continuous IV infusion of contrast can detect differences in coronary artery stenosis severity during dobutamine stress echocardiography.[82]

There are as yet no published human data on alternative methods for assessing perfusion during stress, such as that induced with the use of a treadmill, bicycle, or pacing. The additional imaging complexities encountered during exercise echocardiography, such as variables of motion and time, present a more challenging environment for implementation of contrast perfusion techniques. Investigative studies have focused on the more "controlled" environment of the pharmacologic stress test to optimize techniques of contrast administration and imaging algorithms. Once the optimal algorithms have been established in the controlled environment of pharmacologic or pacing stress, application will likely follow in the exercise environment. Similarly, there is a large body of literature that documents the usefulness of contrast echocardiography in the assessment of myocardial viability through the demonstration of coronary microvascular capillary integrity during intracoronary injections of contrast in the setting of acute and chronic coronary artery disease.[10,61-65,83-87] Assessment of microvascular integrity by intracoronary contrast echocardiography in the early postinfarction period has been shown to predict short- and intermediate-term (median 22-month follow-up) relative risk for major cardiovascular outcomes.[85] However, limited information exists regarding such applications during intravenously administered contrast. Further understanding of optimal contrast image acquisition and analysis will enable the complementary potential of simultaneous perfusion and function assessments during low-dose dobutamine or vasodilator stress to unmask contractile reserve.

It is apparent that myocardial contrast echocardiography holds promise for the noninvasive assessment of myocardial perfusion in human beings. Recently, myocardial opacification has been achieved even during real-time imaging.[21,27] However, at present, there are many important questions that remain to be answered before the routine application of myocardial contrast echocardiography for perfusion imaging can become a clinical reality. A multicenter study sought to identify the accuracy and feasibility of contrast echocardiography by using one investigational contrast agent for the detection of resting perfusion defects in routine practice; the results from an early experiential phase of a group of novice users showed poor sensitivity when compared with SPECT.[88] The crucial problem of reliably differentiating defects from artifacts, such as those caused by ultrasound attenuation, lateral wall dropout, blooming of the

cavity echo, or other sources, has yet to be resolved. Ongoing intensive investigative efforts seek to determine optimal methodologies for contrast administration (bolus versus infusion), image acquisition (triggered versus real-time; optimal nonlinear technique; acoustic output adjustment for optimal microbubble detection versus destruction), image display (real-time versus intermittent, videotape versus digital), and image analysis and processing (quantitative versus qualitative, postprocessing colorization algorithms versus gray-scale analysis, background subtraction referenced to individual patient versus "normal" patient populations).[89] Additional practical issues that will need to be addressed before contrast stress perfusion assessments can be routinely clinically applicable include the labor intensiveness of the current techniques, the time added to the patient examination because of complex acquisition algorithms, the time required for complex off-line quantitative analysis, and the availability of ultrasound units equipped with harmonic imaging capability. Therefore many issues remain to be worked out before perfusion detection with contrast echocardiography will become a standard component of the practice of stress echocardiography.[90] However, with further understanding of ultrasound-microbubble interactions leading to refinements in ultrasound technology as outlined above, it is anticipated that achievement of the ultimate goal of noninvasive echocardiographic assessment of both cardiac function and myocardial perfusion will be met.

In addition to investigations into the application of contrast echocardiography to myocardial perfusion detection, techniques are being developed and validated for new applications, including assessments of coronary artery flow detection and flow reserve measurement,[91,92] endothelial integrity,[93] intracavitary pressure measurements,[94] and targeted delivery of drugs, ligands, and genes.[95]

TRAINING AND EXPERIENCE

The basic prerequisites for independent competence in echocardiography (Training Level 2) must be met before introduction of experience with contrast. Level 2 training is defined as including a minimum of 6 months of echocardiography education, involving 300 studies with a wide variety of abnormalities.[96] Special competence in stress echocardiography training, as outlined by the American Society of Echocardiography, is also recommended.[97] Cardiac sonographers should be well experienced and credentialed in echocardiography.

Beyond these basic prerequisites, the use of contrast in rest and/or stress echocardiograms optimally requires a level of experience through exposure and performance, initially with guidance and supervision. To optimize the benefit to be gained in different clinical settings, physicians and sonographers are encouraged to undertake the pursuit of courses, tutorials, and preceptorships to learn the appropriate techniques for administration of contrast agents and interpretation of contrast-enhanced echocardiograms. It is anticipated that additional training will be required when contrast perfusion studies become a clinical reality, as the techniques for LVO enhancement and perfusion assessment are significantly different. However, the experience with LVO contrast will be valuable to the cardiac sonographer and echocardiographer as a foundation from which to begin when ultrasonic contrast methods are eventually used to assess both function and perfusion.

SUMMARY AND RECOMMENDATIONS

Currently, the use of contrast echocardiography for the improvement of suboptimal rest and stress echocardiography by enhanced definition of the endocardial border is strongly validated. This enhanced definition has enabled improved assessment of cardiac structure and function, as well as diagnostic feasibility and accuracy. The combination of IV contrast with harmonic stress echocardiography is a powerful tool for improved wall motion analysis through enhanced image quality, routinely permitting evaluation of patients with suboptimal images. In this era of cost containment, we await results from studies in large populations addressing resource use and cost-effectiveness to evaluate the need for contrast in patients other than those with suboptimal 2-dimensional or Doppler echocardiograms.

Unique information regarding myocardial perfusion, functional assessment of the coronary vasculature, endothelial function, and therapeutic applications are evolving. Simultaneous acquisition of myocardial function and perfusion information is in developmental phases. Noninvasive imaging of coronary arteries with the use of contrast-enhanced transthoracic harmonic echocardiography and Doppler promises to expand the field of diagnostic and experimental echocardiography, bringing new insight to the pathophysiology of ischemic and nonischemic heart disease. Other future potential applications of contrast echocardiography, including assessment of endothelial function and targeted delivery of diagnostic and therapeutic agents, are areas of inten-

sive investigative research that do not currently have established clinical application.

To ensure quality control and maximize benefit to patients, the American Society of Echocardiography recommends that appropriately trained (Training Level 2 or 3) physicians and cardiac sonographers and the laboratories in their institutions establish an effective system for the performance of contrast echocardiography according to the following guidelines:

1. Intravenous injection of approved contrast agents is useful for enhancement of 2-dimensional echocardiographic images and Doppler spectral recordings in patients with suboptimal studies. Existing publications have defined suboptimal 2-dimensional and Doppler studies as those in which 2 of 6 segments in a standard apical echocardiographic view are not visualized on baseline study, and an inability to obtain a recording of the complete maximal velocity from Doppler spectral profiles, respectively.
2. There are insufficient data at the present time to recommend the "routine" use of contrast agents in all patients. The results of well-controlled clinical trials and observational series with sufficiently powered patient samples to evaluate long-term clinical and economic outcomes are pending.
3. High-quality echocardiographic equipment, preferably with harmonic imaging capability and mechanical index (acoustic output level) display and adjustment, should be available to optimize contrast studies.
4. Physicians should meet current American Society of Echocardiography and American College of Cardiology guidelines for independent echocardiographic interpretation (Training Level 2 or 3). Cardiac sonographers should be experienced and credentialed in echocardiography. Additional didactic and practical training for contrast LVO should include appropriate handling and administration of agents, adjustment of the ultrasound instrument, and recognition and delineation of artifacts. This training can be obtained through course instruction and/or working with experienced colleagues. At present, the proceeding recommendations apply only for LV opacification, as contrast perfusion imaging is still investigational. It is anticipated that guidelines will be further modified for the application of myocardial perfusion contrast echocardiography.
5. Sonographers should be encouraged to identify patients who may benefit from contrast echocardiography and to assist in the administration of contrast agents to achieve optimal images. Determination of credentials and supervision required for administration of contrast agents (IV placement and injection of contrast) is to be guided by individual institutional policies, adhering to local and state requirements.
6. The use of contrast agents for assessment of myocardial perfusion, while promising, is investigational at present and not currently recommended for clinical diagnosis.

REFERENCES

1. Cohen JL, Cheirif J, Segar DS, Gillam LD, Gottdiener JS, Hausnerova E, et al. Improved left ventricular endocardial border delineation and opacification with Optison (FS069), a new echocardiographic contrast agent: results of a phase III multicenter trial. J Am Coll Cardiol 1998;32: 746-52.
2. Ginzberg E. Health services research. Cambridge (MA): Harvard University Press; 1991. p. 1-20.
3. Gramiak R, Shah PM. Echocardiography of the aortic root. Invest Radiol 1968;3:356-66.
4. Kerber RE, Kioschos JM, Lauer RM. Use of an ultrasound contrast method in the diagnosis of valvular regurgitation and intracardiac shunt. Am J Cardiol 1974;34:722-7.
5. Seward JB, Tajik AJ, Hagler DJ, Ritter DG. Contrast echocardiography in single or common ventricle. Circulation 1977;55:513-9.
6. Callahan JA, Seward JB, Nishimura RA, Miller FA Jr, Reeder GS, Shub C, et al. Two-dimensional echocardiographically guided pericardiocentesis: experience in 117 consecutive patients. Am J Cardiol 1985;55:476-9.
7. Kaul S, Kelly P, Oliner JD, Glasheen WP, Keller MW, Watson DD. Assessment of regional myocardial blood flow with myocardial contrast two-dimensional echocardiography. J Am Coll Cardiol 1989;13:468-82.
8. Tei C, Sakamaki T, Shah PM, Meerbaum S, Shimovra K, Kondo S, et al. Myocardial contrast echocardiography: a reproducible technique for identifying regional perfusion deficits. Circulation 1983;67:585-93.
9. Kaul S, Pandian NG, Okada RD, Pohost GM, Weyman AE. Contrast echocardiography in acute myocardial ischemia: I. In-vivo determination of total left ventricular "area at risk." J Am Coll Cardiol 1984;4:1272-82.
10. Sabia PJ, Powers ER, Jayaweera AR, Ragosta M, Kaul S. Functional significance of collateral blood flow in patients with recent acute myocardial infarction: a study using myocardial contrast echocardiography. Circulation 1992;85: 2080-89.
11. Ragosta M, Camarano G, Kaul S, Powers ER, Sarembock IJ, Gimple LW. Microvascular integrity indicates myocellular viability in patients with recent myocardial infarction: new insights using myocardial contrast echocardiography. Circulation 1994;89:2562-69.
12. Villarraga HR, Foley DA, Aeschbacher BC, Klarich KW, Mulvagh SL. Destruction of contrast microbubbles during ultrasound imaging at conventional power output. J Am Soc Echocardiogr 1997;10:783-91.
13. Wei K, Skyba DM, Fischke C, Lindner JR, Jayaweera AR, Kaul S. Interaction between microbubbles and ultrasound: in

vitro and in vivo observations. J Am Coll Cardiol 1997;29: 1081-8.
14. De Jong N, Ten Cate FJ, Lancee CT, Roelandt JR, Bom N. Principles and recent developments in ultrasound contrast agents. Ultrasonics 1991;29:324-30.
15. Burns PN. Harmonic imaging with ultrasound contrast agents. Clinical Radiology 1996;51(Suppl 1):50-5.
16. Mulvagh SL, Foley DA, Aeschbacher BC, Klarich KW, Seward JB. Second harmonic imaging of intravenously administered echocardiographic contrast: visualization of coronary arteries and measurement of coronary blood flow. J Am Coll Cardiol 1996;27:1519-25.
17. Al-Mansour HA, Mulvagh SL, Pumper GM, Klarich KW, Foley DA. Usefulness of harmonic imaging for left ventricular opacification and endocardial border delineation by Optison. Am J Cardiol 2000;85:43-6.
18. Allen MR, Pellikka PA, Villarraga HR, Klarich KW, Foley DA, Mulvagh SL, et al. Harmonic imaging: echocardiographic enhanced contrast intensity and duration. Int J Card Imaging 1999;15:215-20.
19. Porter TR, Xie F. Transient myocardial contrast following initial exposure to diagnostic ultrasound pressures with minute doses of intravenously injected microbubbles: demonstration and potential mechanisms. Circulation 1995;92:2391-5.
20. Powers JE, Burns PN, Souquet J. Imaging instrumentation for ultrasound contrast agents. In: Nanda NC, Schlief R, Goldberg BB, editors. Advances in echo imaging using contrast enhancement. 2nd ed. Dordrecht: Kluwer Academic Publishers; 1997. p. 139-70.
21. Hope Simpson D, Chin CT, Burns PN. Pulse Inversion Doppler: a new method for detecting nonlinear echoes from microbubble contrast agents. IEEE Trans UFFC 1999;46: 372-82.
22. Porter TR, Kricfeld D, Cheatham S, Li S. The effect of ultrasound frame rate on perfluorocarbon-exposed sonicated dextrose albumin microbubble size and concentration when insonifying at different flow rates, transducer frequencies, and acoustic outputs. J Am Soc Echocardiogr 1997;10:593-601.
23. Wei K, Jayaweera AR, Firoozan S, Linka A, Skyba DM, Kaul S. Quantification of myocardial blood flow with ultrasound-induced destruction of microbubbles administered as a constant venous infusion. Circulation 1998;97:795-99.
24. Porter TR, Li S, Leng J, Grayburn P, Deligonul U. Real-time visualization of myocardial perfusion and wall thickening in human beings with intravenous ultrasonographic contrast and accelerated intermittent harmonic imaging. J Am Soc Echocardiogr 1999;12:266-71.
25. Pelberg RA, Wei K, Kamiyama N, Sklenar J, Bin J Kaul S. Potential advantage of flash echocardiography for digital subtraction of B-mode images acquired during myocardial contrast echocardiography. J Am Soc Echocardiogr 1999;12:85-93.
26. Burns PN, Wilson SR, Hope Simpson D. Pulse inversion imaging of liver blood flow: improved method for characterizing focal masses with microbubble contrast. Invest Radiol 2000;35:58-71.
27. Tiemann K, Lohmeier S, Kuntz S, Koster J, Burns PN, et al. Real-time contrast echo assessment of myocardial perfusion at low emission power: first experimental and clinical results using power pulse inversion imaging. Echocardiography 1999;16:799-809.
28. Feinstein SB, Cheirif J, Ten Cate FJ, Silverman PR, Heidenreich PA, Dick C, et al. Safety and efficacy of a new transpulmonary ultrasound contrast agent: initial multicenter clinical results. J Am Coll Cardiol 1990;16:316-24.
29. Shaw LJ, Gillam L, Feinstein S, Dent J, Plotnick G. Technology assessment in the managed care era: use of an intravenous contrast agent (FS069-Optison) to enhance cardiac diagnostic testing. Am J Manag Care 1998;4:SP169-176.
30. Grayburn PA, Weiss JL, Hack TC, Klodas E, Raichlen JS, Vannan MA, et al. Phase III multicenter trial comparing the efficacy of 2% dodecafluoropentane emulsion (EchoGen) and sonicated 5% human albumin (Albunex) as ultrasound contrast agents in patients with suboptimal echocardiograms. J Am Coll Cardiol 1998;32:230-6.
31. Kitzman DW, Goldman ME, Hack TC, Gillam LD, Fenster PE, Segar DS. Efficacy of DMP-115 contrast for left ventricular evaluation in patients with suboptimal baseline images: a multicenter, double blind, randomized, placebo controlled trial [abstract]. J Am Soc Echocardiogr 1998;11:555.
32. Hundley WG, Kizilbash AM, Afridi I, Franco F, Peshock RM, Grayburn PA. Administration of an intravenous perfluorocarbon contrast agent improves echocardiographic determination of left ventricular volumes and ejection fraction: comparison with cine magnetic resonance imaging. J Am Coll Cardiol 1998;32:1426-32.
33. Linder JR, Dent JM, Moos SP. Enhancement of left ventricular cavity opacification by harmonic imaging after venous injection of Albunex. Am J Cardiol 1997;79:1657-62.
34. Al-Mansour HA, Mulvagh SL, Foley DA, Pumper GM, Seward JB. Is harmonic contrast echocardiography the procedure of choice for optimal endocardial border definition [abstract]? J Am Soc Echocardiogr 1998;11:527.
35. Waggoner AD, Williams GA, Gaffron D, Schwarze M. Potential Utility of left heart contrast agents in diagnosis of myocardial rupture by 2-dimensional echocardiography. J Am Soc Echocardiogr 1999;12:272-4.
36. Kimura BJ, Phan JN, Housman LB. Utility of contrast echocardiography in the diagnosis of aortic dissection. J Am Soc Echocardiogr 1999;12:155-9.
37. Nagai T, Atar S, Luo H, Naqvi T, Siegel RJ. The usefulness of second generation ultrasound contrast agent to identify intracardiac thrombus [abstract]. J Am Coll Cardiol 1999;33: 408A.
38. Bootsma M, Schalij MJ, Baur LHB. Diagnosis of arrhythmogenic right ventricular dysplasia by contrast echocardiography [abstract]. J Am Coll Cardiol 1999;33:408A.
39. Pellikka PA, Roger VL, Oh JK, Miller FA, Seward JB, Tajik AJ. Stress echocardiography. Part II. Dobutamine stress echocardiography: techniques, implementations, clinical applications, and correlations. Mayo Clin Proc 1995;70:16-27.
40. Roger VL, Pellikka PA, Oh JK, Miller FA, Seward JB, Tajik AJ. Stress echocardiography. Part 1. Exercise echocardiography: techniques, implementations, clinical applications, and correlations. Mayo Clin Proc 1995;70:5-15.
41. McCully RB, Roger VL, Mahoney DW, Karon BL, Oh JK, Miller FA, et al. Outcome after normal exercise echocardiography and predictors of subsequent cardiac events: follow-up of 1,325 patients. J Am Coll Cardiol 1998;31:144-9.
42. Fleischmann KE, Hunink MG, Kuntz KM, Douglas PS. Exercise echocardiography or exercise SPECT imaging? A meta-analysis of diagnostic test performance. JAMA 1998; 280:913-20.
43. Marwick TH. Mehta R. Arheart K. Lauer MS. Use of exercise echocardiography for prognostic evaluation of patients with known or suspected coronary artery disease. J Am Coll Cardiol 1997;30:83-90.
44. Chuah SC, Pellikka PA, Roger VL, McCully RB, Seward JB. Role of dobutamine stress echocardiography in predicting

outcome in 860 patients with known or suspected coronary artery disease. Circulation 1998;97:1474-80.
45. Marwick TH, Nemic JJ, Pashkow FJ, Stewart WJ, Salcedo EE. Accuracy and limitations of exercise echocardiography in a routine clinical setting. J Am Coll Cardiol 1992;19:74-81.
46. Hoffman R, Lethen H, Marwick T, Arnese M, Fioretti P, Pingitore A, et al. Analysis of inter-institutional observer agreement in interpretation of dobutamine stress echocardiograms. J Am Coll Cardiol 1996;27:330-6.
47. Crouse LJ, Chierif J, Hanly DE, Kisslo JA, Labovitz AJ, Raichlen JS, et al. Opacification and border delineation improvement with suboptimal endocardial border definition in routine echocardiography: Results of the phase III Albunex multicenter trial. J Am Coll Cardiol 1993;22:1494-1500.
48. Falcone RA, Marcovitz PA, Perez JE, Dittrich HC, Hopkins WE, Armstrong WF. Intravenous Albunex during dobutamine stress echocardiography: enhanced localization of left ventricular endocardial borders. Am Heart J 1995;130:254-8.
49. Schroder K, Agrawal R, Woller H, Schlief R, Schroder R. Improvement of endocardial border delineation in suboptimal stress-echocardiograms using the new left heart contrast agent SHU 508A. Int J Card Imaging 1994;10:45-51.
50. Porter TR, Xie F, Kricsfeld A, Chiou A, Dabestani A. Improved endocardial border resolution during dobutamine stress echocardiography with intravenous sonicated dextrose albumin. J Am Coll Cardiol 1994;23:1440-3.
51. Leischik R, Kuhlmann C, Bruch C, Jeremias A, Buck T, Erbel R. Reproducibility of stress echocardiography using intravenous injection of ultrasound contrast agent (BY 963). Int J Card Imaging 1997;13:387-94.
52. Rainbird AJ, Pellikka PA, Mulvagh SL, McCully RB, Oh JK, Klarich KW, et al. Contrast dobutamine stress echocardiography in 100 consecutive patients: improvement in image quality, wall segment visualization and confidence of interpretation [abstract]. J Am Coll Cardiol 1999;33:422A.
53. Shaw LJ. Impact of contrast echocardiography on diagnostic algorithms: pharmaco-economic implications. Clin Cardiol 1997;20(10 Suppl 1):I39-48.
54. Shaw LJ, Monaghan MJ, Niyannopolous P. Clinical and economic outcomes assessment with myocardial contrast echocardiography. Heart 1999;82(Suppl 3):III16-21.
55. Hagler DJ, Currie PJ, Seward JB, Tajik AJ, Mair DD, Ritter DG. Echocardiographic contrast enhancement of poor or weak continuous-wave Doppler signals. Echocardiography 1987;4:63-7.
56. Terasawa A, Miyatake K, Nakatani S, Yamagishi M, Matsuda H, Beppu S. Enhancement of Doppler flow signals in the left heart chambers by intravenous injection of sonicated albumin. J Am Coll Cardiol 1993;21:737-42.
57. Nakatani S, Imanishi T, Terawawa A, Beppu S, Nagata S, Miyatake K. Clinical application of transpulmonary contrast-enhanced Doppler technique in the assessment of severity of aortic stenosis. J Am Coll Cardiol 1992;20:973-8.
58. Forsberg F, Liu JB, Burns PN, Merton DA, Goldberg BB. Artifacts in ultrasonic contrast agent studies. J Ultrasound Med 1994;13:357-65.
59. Von Bibra H, Sutherland G, Becher H, Neudert J, Nihoyannopoulos P. Clinical evaluation of left heart Doppler contrast enhancement by a saccharide-based transpulmonary contrast agent: The Levovist Cardiac Working Group. J Am Coll Cardiol 1995;25:500-8.
60. Perchet H, Dupouy P, Duval-Moulin AM, Hittinger L, Pelle G, Brun P, et al. Improvement of subendocardial myocardial perfusion after percutaneous transluminal coronary angioplasty: a myocardial contrast echocardiography study with correlation between myocardial contrast reserve and Doppler coronary reserve. Circulation 1995;91:1419-26.
61. Rovai D, Zanchi M, Lombardi M, Magagnini E, Chella P, Pieroni A, et al. Residual myocardial perfusion in reversibly damaged myocardium by dipyridamole contrast echocardiography. Eur Heart J 1996;17:296-301.
62. Meza MF, Ramee S, Collins T, Stapleton D, Milani RV, Murgo JP, et al. Knowledge of perfusion and contractile reserve improves the predictive value of recovery of regional myocardial function post-revascularization: a study using the combination of myocardial contrast echocardiography and dobutamine echocardiography. Circulation 1997;96:3459-65.
63. Nagueh SF, Vaduganathan P, Ali N, Blaustein A, Verani MS, Winters WL Jr, et al. Identification of hibernating myocardium: comparative accuracy of myocardial contrast echocardiography, rest-redistribution thallium-201 tomography and Dobutamine echocardiography. J Am Coll Cardiol 1997;29: 985-93.
64. Ito H, Tomooka T, Sakai N, Yu H, Higashino Y, Fujii K, et al. Lack of myocardial perfusion immediately after successful thrombolysis: a predictor of poor recovery of left ventricular function in anterior myocardial infarction. Circulation 1992; 85:1699-1705.
65. Bolognese L, Antoniucci D, Rovai D, Buonamici P, Cerisano G, Santoro GM, et al. Myocardial contrast echocardiography versus dobutamine echocardiography for predicting functional recovery after acute myocardial infarction treated with primary coronary angioplasty. J Am Coll Cardiol 1996;28: 1677-83.
66. Reisner SA, Ong LS, Lichtenberg GS, Shapiro JR, Amico AF, Allen MN, et al. Quantitative assessment of the immediate results of coronary angioplasty by myocardial contrast echocardiography. J Am Coll Cardiol 1989;12:852-6.
67. Lang RM, Feinstein SB, Feldman T, Neumann A, Chua KG, Borow KM. Contrast echocardiography for the evaluation of myocardial perfusion: effects of coronary angioplasty. J Am Coll Cardiol 1986;8:232-5.
68. Porter TR, D'Sa A, Pesko L, Turner C, Nath A, Vetrovec GW, et al. Usefulness of myocardial contrast echocardiography in detecting the immediate changes in anterograde blood flow reserve after coronary angioplasty. Am J Cardiol 1993; 71:893-6.
69. Lindner JR, Skyba DM, Goodman NC, Jayaweera AR, Kaul S. Changes in myocardial blood volume with graded coronary stenosis. Am J Physiol 1997;272(1 Pt 2):H567-75.
70. Meza MF, Mobarek S, Sonnemaker R, Shuler S, Ramee SR, Collins TJ, et al. Myocardial contrast echocardiography in human beings: correlation of resting perfusion defects to sestamibi single photon emission computed tomography. Am Heart J 1996;132:528-35.
71. Dittrich HC, Bales GL, Kuvelas T, Hunt RM, McFerran BA, Greener Y. Myocardial contrast echocardiography in experimental coronary artery occlusion with a new intravenously administered contrast agent. J Am Soc Echocardiogr 1995;8: 465-74.
72. Meza M, Greener Y, Hunt R, Perry B, Revall S, Barbee W, et al. Myocardial contrast echocardiography: reliable, safe, and efficacious myocardial perfusion assessment after intravenous injections of a new echocardiographic contrast agent. Am Heart J 1996;132:871-81.
73. Beppu S, Matsuda H, Shishido T, Matsumura M, Miyatake K. Prolonged myocardial contrast echocardiography via

peripheral venous administration of QW3600 injection (EchoGen): its efficacy and side. J Am Soc Echocardiogr 1997;10:11-24.
74. Grauer SE, Pantely GA, Xu J, Ge S, Giraud GD, Shiota T, et al. Myocardial imaging with a new transpulmonary lipid-fluorocarbon echocardiography contrast agent: experimental studies in pigs. Am Heart J 1996;132:938-45.
75. Firschke C, Lindner JR, Wei K, Goodman NC, Skyba DM, Kaul S. Myocardial perfusion imaging in the setting of coronary artery stenosis and acute myocardial infarction using venous injection of a second-generation echocardiographic contrast agent. Circulation 1997;96:959-67.
76. Main J, Escobar JF, Hall SA, Killam AL, Grayburn PA. Detection of myocardial perfusion defects by contrast echocardiography in the setting of acute myocardial ischemia with residual antegrade flow. J Am Soc Echocardiogr 1998;11:228-35.
77. Rovai D, Lubrano V, Vassalle C, et al. Detection of perfusion defects during coronary occlusion and myocardial reperfusion after thrombolysis by intravenous administration of the echo-enhancing agent BR1. J Am Soc Echocardiogr 1998;11:169-80.
78. Lindner J, Firschke C, Wei K, Goodman C, Skyba DM, Kaul S. Myocardial perfusion characteristics and hemodynamic profile of MRX-115, a venous echocardiographic contrast agent, during acute myocardial infarction. J Am Soc Echocardiogr 1998;11:36-46.
79. Porter TR, Zie F, Kilzer K, Deligonul U. Detection of myocardial perfusion abnormalities during dobutamine and adenosine stress echocardiography with transient myocardial contrast imaging after minute quantities of intravenous perfluorocarbon-exposed sonicated dextrose albumin. J Am Soc Echocardiogr 1996;9:779-86.
80. Porter TR, Li S, Kricsfeld D, Armbruster RW. Detection of myocardial perfusion in multiple echocardiographic windows with one intravenous injection of microbubbles using transient response second harmonic imaging. J Am Coll Cardiol 1997;29:791-9.
81. Kaul S, Senior R, Dittrich H, Raval U, Khattar R, Lahiri A. Detection of coronary artery disease with myocardial contrast echocardiography: comparison with 99m Tc-sestamibi single-photon emission computed tomography. Circulation 1997; 96:785-92.
82. Porter T, Li S, Kilzer K, Deligonul U. Correlation between quantitative angiographic lesion severity and myocardial contrast intensity during a continuous infusion of perfluorocarbon-containing microbubbles. J Am Soc Echocardiogr 1998; 11:702-10.
83. Ragosta M, Camarano G, Kaul S, Powers ER, Sarembock IJ, Gimple LW. Microvascular integrity indicates myocellular viability in patients with recent myocardial infarction. New insights using myocardial contrast echocardiography. Circulation 1994;89:2562-9.
84. DeFilippi CR, Willett DL, Irani WN, Eichhorn EJ, Velasco CE, Grayburn PA. Comparison of myocardial contrast echocardiography in predicting recovery of left ventricular function after coronary revascularization in chronic ischemic heart disease. Circulation 1995;92:2863-8.
85. Sakuma T, Hayashi Y, Sumii K, Imazu M, Yamakido M. Prediction of short- and intermediate-term prognoses of patients with acute myocardial infarction using myocardial contrast echocardiography one day after recanalization. J Am Coll Cardiol 1998;32:890-7.
86. Vernon S, Kaul S, Powers ER, Camarano G, Gimple LW, Ragosta M. Myocardial viability in patients with chronic coronary artery disease and previous myocardial infarction: comparison of myocardial contrast echocardiography and myocardial perfusion scintigraphy. Am Heart J 1997;134(5 Pt 1):835-40.
87. Agati L, Voci P, Autore C, Luonogo R, Testa G, Mallus MT, et al. Combined use of dobutamine echocardiography and myocardial contrast echocardiography in predicting regional dysfunction recovery after coronary revascularization in patients with recent myocardial infraction. Eur Heart J 1997; 18:771-9.
88. Marwick TH, Brunken R, Meland N, Brochet E, Baer FM, Binder T, et al. Accuracy and feasibility of contrast echocardiography for detection of perfusion defects in routine practice: Comparison with wall motion and technetium-99m sestamibi single-photon emission computed tomography. J Am Coll Cardiol 1998;32:1260-9.
89. Becher H, Burns PN. Handbook of contrast echocardiography. Heidelberg: Springer Verlag. In press.
90. DeMaria AN, Cotter B, Ohmori K. Myocardial contrast echocardiography: too much, too soon? J Am Coll Cardiol 1998;32:1270-1.
91. Voci P, Testa G, Plaustro G. Imaging of the distal left anterior descending coronary artery by transthoracic color-Doppler echocardiography. Am J Cardiol 1998;81(12A):74G-78G.
92. Caiati C, Montaldo C, Zedda N, Bina A, Iliceto S. New noninvasive method for coronary flow reserve assessment: contrast-enhanced transthoracic harmonic echo Doppler. Circulation 1999;99:771-78s.
93. Villanueva FS, Jankowski RJ, Manaugh C, Wagner WR. Albumin microbubble adherence to human coronary endothelium: implications for assessment of endothelial function using myocardial contrast echocardiography. J Am Coll Cardiol 1997;30:689-93.
94. Shi WT, Forsberg F, Raichlen JS, Needleman L, Goldberg BB. Pressure dependence of subharmonic signals from contrast microbubbles. Ultrasound Med Biol 1999;25:275-83.
95. Birnbaum Y, Luo H, Nagai T, Fishbein MC, Peterson TM, Li S, et al. Noninvasive in vivo clot dissolution without a thrombolytic drug: recanalization of thrombosed iliofemoral arteries by transcutaneous ultrasound combined with intravenous infusion of microbubbles. Circulation. 1998;97:130-4.
96. Pearlman AS, Gardin JM, Martin RP, Parisi AF, Popp RL, Quinones, MA, et al. Guidelines for optimal physician training in echocardiography: recommendations of the American Society of Echocardiography Committee for Physician Training in Echocardiography. Am J Cardiol 1987;60:158-63.
97. Popp R, Agatston A, Armstrong W, Nanda N, Pearlman A, Rakowski H, et al. Recommendations for training in performance and interpretation of stress echocardiography. J Am Soc Echocardiogr 1998;11:95-6.