Microbubble Contrast Agents for Ultrasound Imaging—Safety and Efficacy in Abdominal and Vascular Imaging

a report by

Tae Kyoung Kim, MD,[1] Hyun-Jung Jang, MD[2] *and* **Stephanie R Wilson, MD[3]**

1. Associate Professor of Radiology, University of Toronto; 2. Assistant Professor of Radiology, University of Toronto; 3. Professor of Radiology, University of Calgary

The use of contrast agents is an essential component of abdominal computed tomography (CT) and magnetic resonance (MR) examination. However, the use of contrast agents in ultrasound has not been as popular in North America, as at the time of writing they are not approved in the US for clinical use in abdominal imaging. We have enjoyed using contrast-enhanced ultrasound (CEUS) in Canada, where contrast agents for ultrasound have been approved for abdominal imaging since 2001. In our experience, CEUS is an excellent imaging modality with a strong safety profile and superb diagnostic capability for many indications in abdominal imaging.[1] CEUS is also widely available in Europe and East Asia, and the use of CEUS has rapidly increased over recent years. This article provides a summary of our experience with CEUS in liver and other abdominal imaging.

Tae Kyoung Kim, MD, is an Associate Professor of Radiology at the University of Toronto. His research focuses on the cross-sectional imaging of primary liver tumors. He has published over 100 papers in peer-reviewed journals and is also a reviewer for radiology journals such as *Radiology* and *European Radiology*. He has given lectures regarding hepatobiliary imaging at annual meetings of major radiological societies, including the Radiological Society of North America (RSNA), the American Roentgen Ray Society (ARRS), and the World Federation of Ultrasound in Medicine and Biology (WFUMB). Dr Kim graduated from the Seoul National University in 1991 and completed his radiology residency and abdominal imaging fellowship at Seoul National University Hospital.

Hyun-Jung Jang, MD, is an Assistant Professor of Radiology at the University of Toronto. She is an abdominal radiologist and her main research interest is in liver imaging. She has published over 40 papers and contributed to a number of review articles. Dr Jang has given talks regarding liver imaging and contrast ultrasound to major radiological societies, including the Radiological Society of North America (RSNA) and the American Roentgen Ray Society (ARRS). She completed her medical education and radiology training at Seoul National University and Samsung Medical Center.

Stephanie R Wilson, MD, is a Professor of Radiology at the University of Calgary and a Member of the Diagnostic Imaging Department at Foothills Medical Centre. Her research focuses on imaging of the gastrointestinal tract, pancreas, and liver. She has been the recipient of many prestigious University of Toronto Faculty of Medicine teaching awards, including the Colin R Woolf Award for Excellence in Continuing Education Teaching. Dr Wilson is co-editor of the textbook *Diagnostic Ultrasound*. She was the first woman President of the Canadian Association of Radiologists in 1993, and was later awarded the Canadian Association of Radiologists Gold Medal in 2001 for her contributions to Canadian radiology. She has written over 100 peer-reviewed publications and is an active member of the Radiological Society of North America (RSNA), among others. Dr Wilson graduated in medicine with distinction from the University of Alberta.

E: Stephanie.Wilson@calgaryhealthregion.ca

What Is the Contrast Agent for Ultrasound?

Contrast agents for ultrasound comprise gas-filled microbubbles with a mean diameter less than that of red blood cells. The first-generation contrast agents for ultrasound contained room air coated with galactose microcrystals (Levovist) or denatured albumin (Albunex). However, the enhancement of this generation of agents necessitated the disruption of the microbubbles with a high power output (mechanical index [MI]). Therefore, CEUS studies were technically challenging as the microbubbles are disrupted as they enter the field of view, limiting their effect. These contrast agents are no longer in common use. Second-generation contrast agents for ultrasound that are popular today typically contain perfluorocarbon gases such as perfluoropropane (Definity, Lantheus Medical Imaging, Billerica) or sulfur hexafluoride (SonoVue, Bracco, Milan), and are encapsulated with phospholipid shells. These contrast agents show strong enhancement without microbubble disruption using a contrast-specific imaging mode with a low MI.[2] These microbubbles have excellent durability, enabling continuous realtime imaging over three to five minutes.

Are Microbubble Contrast Agents Different from Contrast Agents for Computed Tomography or Magnetic Resonance Imaging?

Microbubble contrast agents for ultrasound are completely different from those used for either CT or MR scans. These differences include their chemical composition, mechanism of action, and safety. Their similarities include effective liver enhancement, allowing for non-invasive diagnosis of liver masses. Microbubble contrast agents for ultrasound show concordant enhancement patterns with contrast-enhanced CT or MR scans in the majority of cases.[3] However, there are a few unique features of microbubbles that differ from those of CT or MR contrast imaging and which contribute to the value of CEUS in a multimodality approach to liver mass imaging.

First, microbubbles for CEUS are purely intravascular, whereas CT or MR contrast agents can diffuse through the vascular endothelium into the interstitium. This difference is potentially beneficial for CEUS to characterize malignant liver tumors with high vascular permeability and large interstitial space by demonstrating wash-out phenomenon more clearly than either CT or MR.[4] This is particularly relevant for non-hepatocyte-based liver tumors such as metastases and cholangiocarcinoma.

Second, CEUS provides realtime dynamic imaging, which is useful for visualization of the enhancement pattern of liver masses in the arterial phase, superior to CT or MR scans, where a fixed-time delay is typically used. Realtime imaging is particularly useful to characterize hypervascular

© TOUCH BRIEFINGS 2008

liver malignancies[5] or other rapidly enhancing hypervascular masses such as focal nodular hyperplasia or rapid-filling hemangiomas.[6]

Third, microbubbles can be injected multiple times during a single CEUS examination. The first injection is typically used for continuous evaluation of the lesion for three to five minutes. Subsequent injections are used for detailed evaluation of arterial enhancement patterns and vascular morphology, or for evaluating other lesions in cases with multiple lesions. In comparison, contrast agents for CT and MR scans are injected only once during a single examination.

Finally, microbubbles can be quickly cleared from the scanning plane by using high-MI ultrasound. Following a brief high-MI insonation, the re-filling of the vasculature with the microbubbles may be monitored—the so-called flash-replenishment technique. This technique is useful to evaluate arterial-phase filling patterns and vascular morphology, and is also the most reliable method to quantify vascular volume and flow rates.[2] In conjunction with flash-replenishment, the maximum intensity projection technique is extremely useful for visualizing vascular morphology in rapidly enhancing masses as well as normal tissue.[7]

Are Microbubble Contrast Agents Safe?

Microbubble contrast agents are non-toxic and most patients are totally unaware of their injection. The adverse event rate is extremely low at 0.13% (29 per 23,988 examinations), as reported in the largest study from Europe, which included serious adverse reactions in two patients (0.0086%).[8] Two very important advantages of CEUS include complete absence of nephrotoxicity and lack of exposure to ionizing radiation. Moreover, there is no risk of skin infection or necrosis from interstitial injection as the amount injected is so small. CEUS can be easily performed in patients with claustrophobia.

What Are the Common Indications for Contrast-enhanced Ultrasound?

CEUS is most effective when used for specific and well-designed indications in abdominal imaging. The major established application is for characterization of focal liver masses. Other abdominal organs that can be evaluated with CEUS include the kidney, aorta, prostate, spleen, bowel, and pelvic organs.

Characterization of Incidentally Detected Liver Masses

The majority of incidentally detected liver masses in otherwise healthy patients are benign. CEUS is excellent for characterizing common benign masses such as hemangioma, focal nodular hyperplasia (see *Figure 1*), and focal fat deposits or sparing.[6,9] Suspicious liver masses on CEUS can be referred to other imaging modalities or biopsy in a timely manner.[10] Immediate performance of CEUS at the time of detection of the mass on routine ultrasound examination leads to a reduced time to diagnosis, patient anxiety, and time to referral for other imaging examinations.[1]

Resolution of Indeterminate Liver Masses on Computed Tomography or Magnetic Resonance Scan

CEUS is useful for characterizing focal liver masses showing indeterminate imaging findings on CT or MR scan. One of the frequent examples is small non-specific hypoattenuating lesions seen on CT scan (see *Figure 2*). The realtime imaging capability of CEUS and the use of a purely intravascular agent can frequently provide further diagnostic information that is helpful in the process of characterizng difficult liver masses.[1,4]

Figure 1: Focal Nodular Hyperplasia

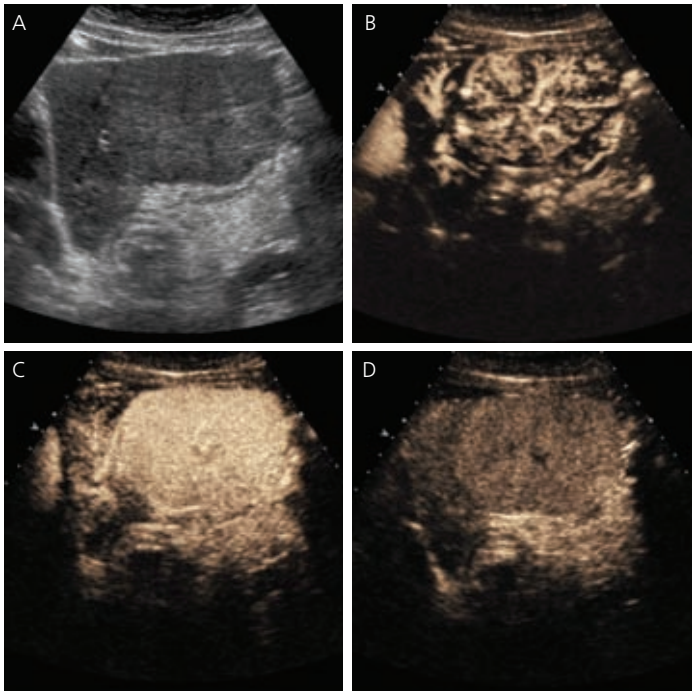

A: A sagittal image through the left lobe of the liver shows an isoechoic expansive mass. B: An early arterial phase image shows stellate vascularity. C: At the peak of enhancement, the mass shows uniform homogenous hypervascularity. D: A portal venous phase image at four minutes shows sustained enhancement, indicative of a benign lesion—focal nodular hyperplasia. It also shows a classic stellate central unenhancing scar.

Figure 2: Metastasis from Colon Cancer

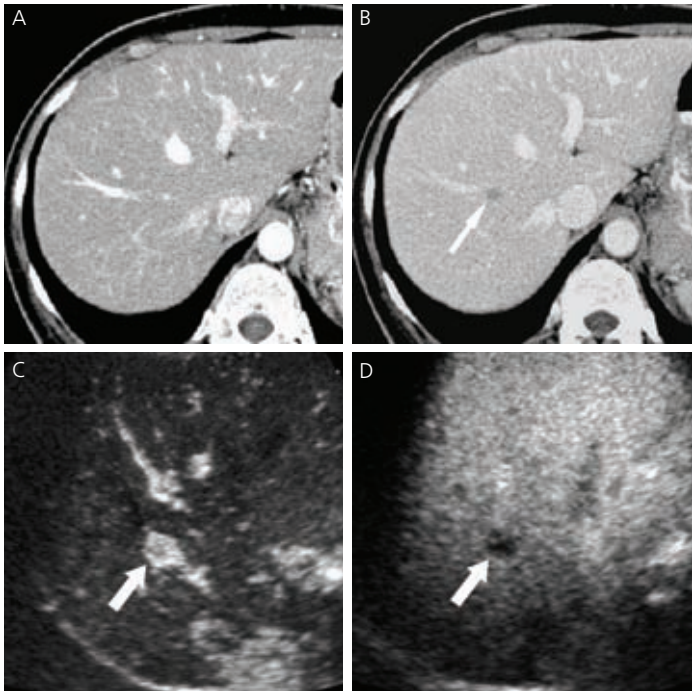

A and B: A computed tomography (CT) scan through the liver in a patient with colon cancer shows a non-specific small hypoattenuating lesion on the portal venous phase scan (B). The lesion is not seen on arterial phase scan (A). C: A contrast-enhanced ultrasound (CEUS) scan in the arterial phase shows strong homogeneous enhancement of the lesion. D: The lesion shows wash-out in the portal venous phase. Positive enhancement in the arterial phase and washout in the portal venous phase is a characteristic feature of malignancy.

Figure 3: Hemangioma

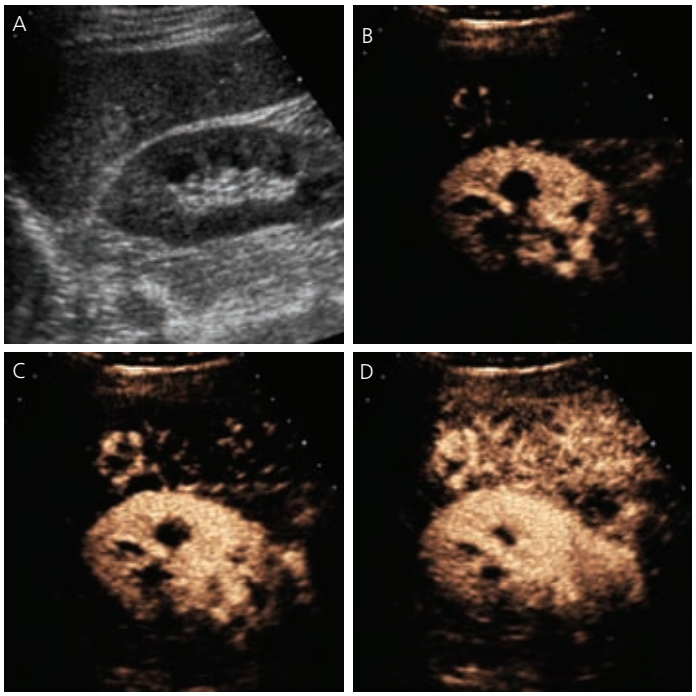

A: An image from a surveillance ultrasound for a patient at risk for hepatocellular carcinoma shows a small mass in the kidney. B, C, and D: Sequential images taken in the arterial phase showing first rim enhancement, peripheral nodules, and then centripetal progression of enhancement. These characteristics are typical of hemangioma.

Figure 4: Hepatocellular Carcinoma

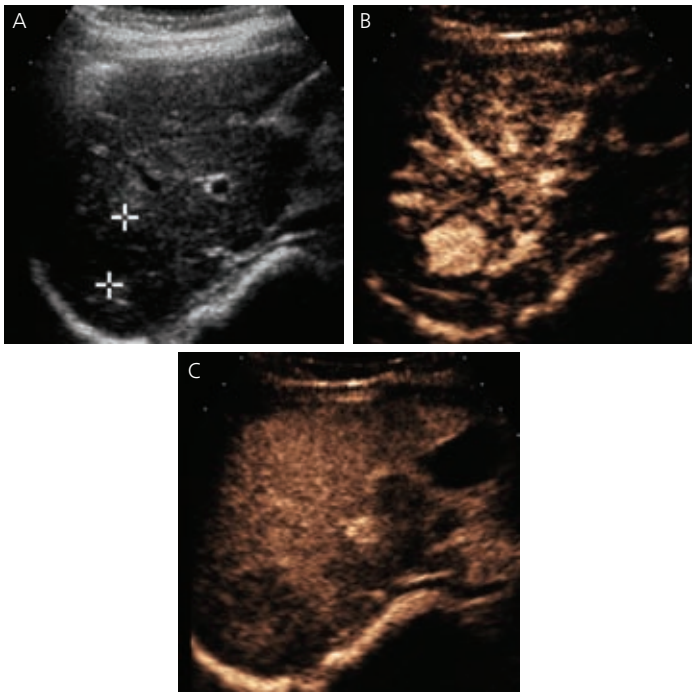

A: An image from a surveillance scan in a patient at risk for hepatocellular carcinoma shows a small hypoechoic mass in the liver (asterisks). B: An arterial phase image from CEUS shows the mass is hypervascular, appearing brighter than the adjacent liver parenchyma. C: In the portal venous phase, there is washout of the mass such that it appears less enhanced than the adjacent liver, the classic pattern for a malignant tumor, in this case hepatocellular carcinoma.

Characterization of Small Nodules in Liver Cirrhosis

The differential diagnosis of small nodules in liver cirrhosis is challenging.[11] CEUS is an excellent imaging modality to show vascularity of the nodule with a high temporal resolution (see *Figures 3* and *4*).[12] A recent trend is to make a non-invasive diagnosis of small (1–2cm) typical hepatocellular carcinoma (HCC) using a multimodality approach. The importance of CEUS is recognized by the American Association for the Study of Liver Diseases (AASLD), and CEUS has been included in the practice guideline for the management of small nodules detected in surveillance for HCC.[13] There is a wide variation of enhancement patterns in borderline lesions such as high-grade dysplastic nodules and well-differentiated HCC. We have recognized the valuable contribution of CEUS when used with contrast-enhanced CT and MR imaging in this challenging situation.

Figure 5: Monitoring of Radiofrequency Ablation

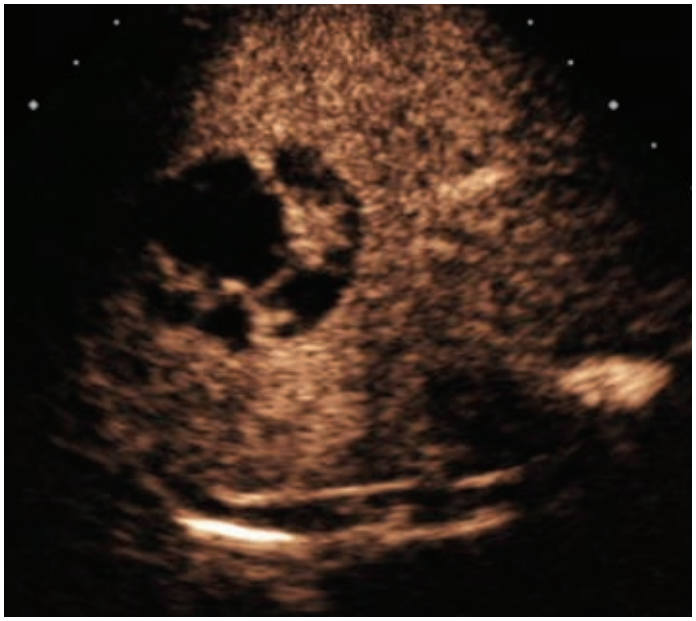

Contract-enhanced ultrasound (CEUS) arterial phase image shows multiple enhancing nodules within the ablation zone, which is otherwise black or unenhanced.

Monitoring Therapeutic Response to Radiofrequency Ablation for Hepatocellular Carcinoma

An accurate assessment of the therapeutic response to radiofrequency ablation (RFA) for HCC is crucial because a residual or recurrent HCC may immediately require an additional treatment. CEUS can be performed immediately after an RFA procedure so that repeated RFA can be carried out immediately after the procedure (see *Figure 5*) or can be used as a useful alternative or a problem-solving method when CT or MR imaging is not conclusive.[14,15] CEUS can be also used as a guidance to place the needle within the lesion during an RFA procedure in cases with inadequate visibility of the lesion on grayscale ultrasound.

Sensitive Prediction of Type of Malignancy Based on Wash-out Times of Liver Masses on Contrast-enhanced Ultrasound

In agreement with CT and MR scans, the wash-out of lesions on CEUS is suggestive of malignancy. Unique to CEUS is the valuable differentiation of the type of malignancy based on the timing of the wash-out. Our investigations and those of others support that metastases wash-out rapidly, often within the time-frame of the arterial phase,[16] whereas HCC tends to show slower and incomplete wash-out and, in small numbers, no wash-out.[12]

Figure 6: Cystic Renal Cell Carcinoma

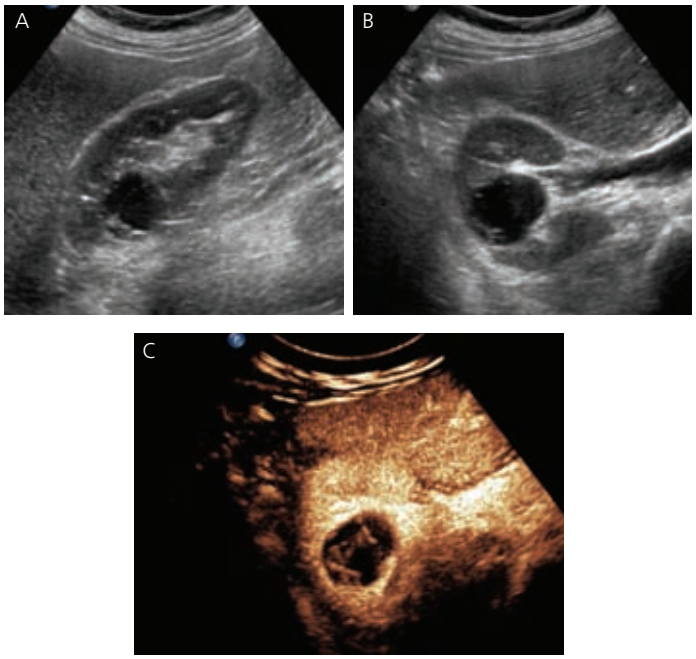

A and B: Long-axis and cross-sectional images of the kidney show a cyst with some internal complexity in the mid-pole of the kidney. C: An arterial phase contrast-enhanced ultrasound (CEUS) image shows enhancement of the normal renal parenchyma and the internal components of the cystic mass confirmatory for cystic renal cell carcinoma.

Characterization of Complex Renal Cysts

The differentiation of cystic renal cell carcinoma (RCC) from complex benign cysts remains a common and difficult diagnostic problem. Contrast-enhanced CT is most commonly used to characterize complex cystic renal lesions. CEUS can be a useful alternative to CT in this indication. Our experience shows that CEUS demonstrates enhancing septa or nodules in cystic RCC (see *Figure 6*). Ascenti et al.[17] recently reported that CEUS is an appropriate test for renal cyst classification with the Bosniak system.

Surveillance of Endoleak After Abdominal Aortic Endograft

Abdominal aortic endografts are increasingly used to exclude the aortic aneurysm worldwide. Contrast-enhanced CT is a standard imaging modality to detect an endoleak, which is an incomplete exclusion of an aneurysm resulting in the leakage of blood into the aneurysmal sac. CEUS is a practical alternative to CT for annual surveillance because it is readily available and inexpensive, and can be used safely in patients with impaired renal function.[18]

Figure 7: Inflammatory Bowel Disease

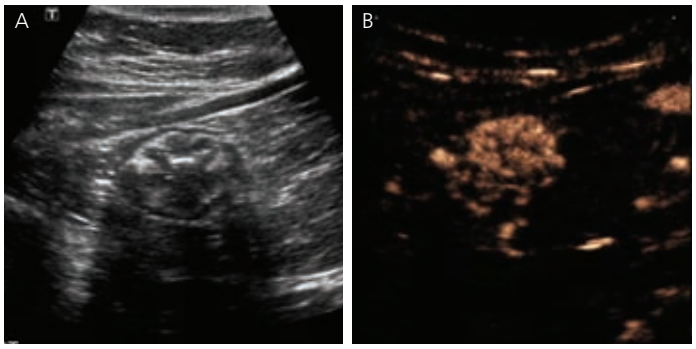

A: A cross-sectional image through the terminal ileum in a symptomatic patient with known Crohn's disease shows bowel wall thickening. B: An arterial phase image with contrast-enhanced ultrasound (CEUS) shows transmural enhancement of the bowel wall consistent with active inflammatory disease.

Other Indications

Common splenic lesions such as hemangioma, hamartoma, or accessory spleen can be diagnosed with CEUS.[19] CEUS can also be useful to determine disease activity of inflammatory bowel disease (see *Figure 7*).[20] Another important potential utility of CEUS is monitoring therapeutic response to antiangiogenic therapy for various abdominal malignancies. With the development of antiangiogenic agents, tumor size measurement has become inappropriate as there is no reduction of tumor size. Therefore, functional studies are necessary and CEUS is one of the imaging techniques under evaluation for monitoring treatments along with dynamic contrast-enhanced CT or MR imaging.[21]

Conclusion

As a safe, easily performed, and highly effective imaging technique that does not utilize ionizing radiation and has no renal toxicity, CEUS should be established as one of the routine imaging modalities in abdominal imaging. ■

Supported by Lantheus Medical Imaging. The views are those of the authors and not necessarily those of Lantheus Medical Imaging.

1. Lanka B, et al., Impact of contrast-enhanced ultrasonography in a tertiary clinical practice, *J Ultrasound Med*, 2007;26:1703–14.
2. Burns PN, Wilson SR, Microbubble contrast for radiological imaging: 1, *Principles Ultrasound Q*, 2006;22:5–13.
3. Burns PN, Wilson SR, Focal Liver Masses: Enhancement Patterns on Contrast-enhanced Images—Concordance of US Scans with CT Scans and MR Images, *Radiology*, 2007;242:162–74.
4. Wilson SR, Kim TK, Jang HJ, Burns PN, Enhancement patterns of focal liver masses: discordance between contrast-enhanced sonography and contrast-enhanced CT and MRI, *AJR Am J Roentgenol*, 2007;189:W7–12.
5. Jang HJ, Kim TK, Wilson SR, Imaging of malignant liver masses: characterization and detection, *Ultrasound Q*, 2006;22:19–29.
6. Kim TK, Jang HJ, Wilson SR, Benign liver masses: imaging with microbubble contrast agents, *Ultrasound Q*, 2006;22:31–9.
7. Wilson SR, Jang HJ, Kim TK, et al., Realtime temporal maximum-intensity-projection imaging of hepatic lesions with contrast-enhanced sonography, *AJR Am J Roentgenol*, 2008;190:691–5.
8. Piscaglia F, Bolondi L, The safety of Sonovue in abdominal applications: retrospective analysis of 23,188 investigations, *Ultrasound Med Biol*, 2006;32:1369–75.
9. Kim TK, Jang HJ, Burns PN, et al., Focal nodular hyperplasia and hepatic adenoma: differentiation with low-mechanical-index contrast-enhanced sonography, *AJR Am J Roentgenol*, 2008;190:58–66.
10. Wilson SR, Burns PN, An algorithm for the diagnosis of focal liver masses using microbubble contrast-enhanced pulse-inversion sonography, *AJR Am J Roentgenol*, 2006;186:1401–12.
11. Kim TK, Jang HJ, Wilson SR, Imaging diagnosis of hepatocellular carcinoma with differentiation from other pathology, *Clin Liver Dis*, 2005;9:253–79.
12. Jang HJ, Kim TK, Burns PN, Wilson SR, Enhancement patterns of hepatocellular carcinoma at contrast-enhanced US: comparison with histologic differentiation, *Radiology*, 2007;244:898–906.
13. Bruix J, Sherman M, Management of hepatocellular carcinoma, *Hepatology*, 2005;42:1208–36.
14. Solbiati L, Tonolini M, Cova L, Monitoring RF ablation, *Eur Radiol*, 2004;14(Suppl. 8):P34–42.
15. Dill-Macky MJ, et al., Radiofrequency ablation of hepatocellular carcinoma: predicting success using contrast-enhanced sonography, *AJR Am J Roentgenol*, 2006;186:S287–95.
16. Murphy-Lavallee J, Jang HJ, Kim TK, et al., Are metastases really hypovascular in the arterial phase? The perspective based on contrast-enhanced ultrasonography, *J Ultrasound Med*, 2007;26:1545–56.
17. Ascenti G, Mazziotti S, Zimbaro G, et al., Complex cystic renal masses: characterization with contrast-enhanced US, *Radiology*, 2007;243:158–65.
18. Dill-Macky MJ, Wilson SR, Sternbach Y, et al., Detecting endoleaks in aortic endografts using contrast-enhanced sonography, *AJR Am J Roentgenol*, 2007;188:W262–8.
19. Gorg C, The forgotten organ: contrast enhanced sonography of the spleen, *Eur J Radiol*, 2007;64:189–201.
20. Serra C, Menozzi G, Labate AM, et al., Ultrasound assessment of vascularization of the thickened terminal ileum wall in Crohn's disease patients using a low-mechanical index real-time scanning technique with a second generation ultrasound contrast agent, *Eur J Radiol*, 2007;62:114–21.
21. Lassau N, Chami L, Benatsou B, et al., Dynamic contrast-enhanced ultrasonography (DCE-US) with quantification of tumor perfusion: a new diagnostic tool to evaluate the early effects of antiangiogenic treatment, *Eur Radiol*, 2007;17(Suppl. 6):F89–98.